

Hip ultrasound refresher course according to Graf

Refresher course US according to Graf

When:	Saturday, November 14th, 2026
Where:	Lecture hall SRO, St. Urbanstrasse 67, 4900 Langenthal
Instructor:	Dr. med. Veit Vassen
Course language:	English
Contact/Registration:	v.vassen@sro.ch
Cost:	CHF 500,- CHF 300,- Member SGUM Confirmation of participation only after receipt of payment
Transfer to:	Hüft-US-Refresher Veit Manfred Vassen 4900 Langenthal IBAN CH15082520267347P000C
Course duration:	8h
CME	7 Credits SGR

*The course is open to all certificate holders or all specialist groups

Program

08:30 – 09:00	Arrival of the participants
09:00 – 10:00	Location determination
10:00 – 10:30	Coffee break*
10:30 – 12:30	Basics (anatomical identification, usability testing, Graf classification)
12:30 – 13:30	Lunch break
13:30 – 15:00	Description, measurement technology, fine typing, etc.
15:00 – 15:30	Pause*
15:30 – 17:00	Practice with examples
17:00 – 18:00	Analysis of the images brought
Ca. 18:00	End

*During the breaks, the 10 + 10 pictures brought with each candidate will be viewed and analyzed if they have not already been assessed beforehand.

Recertification requirement

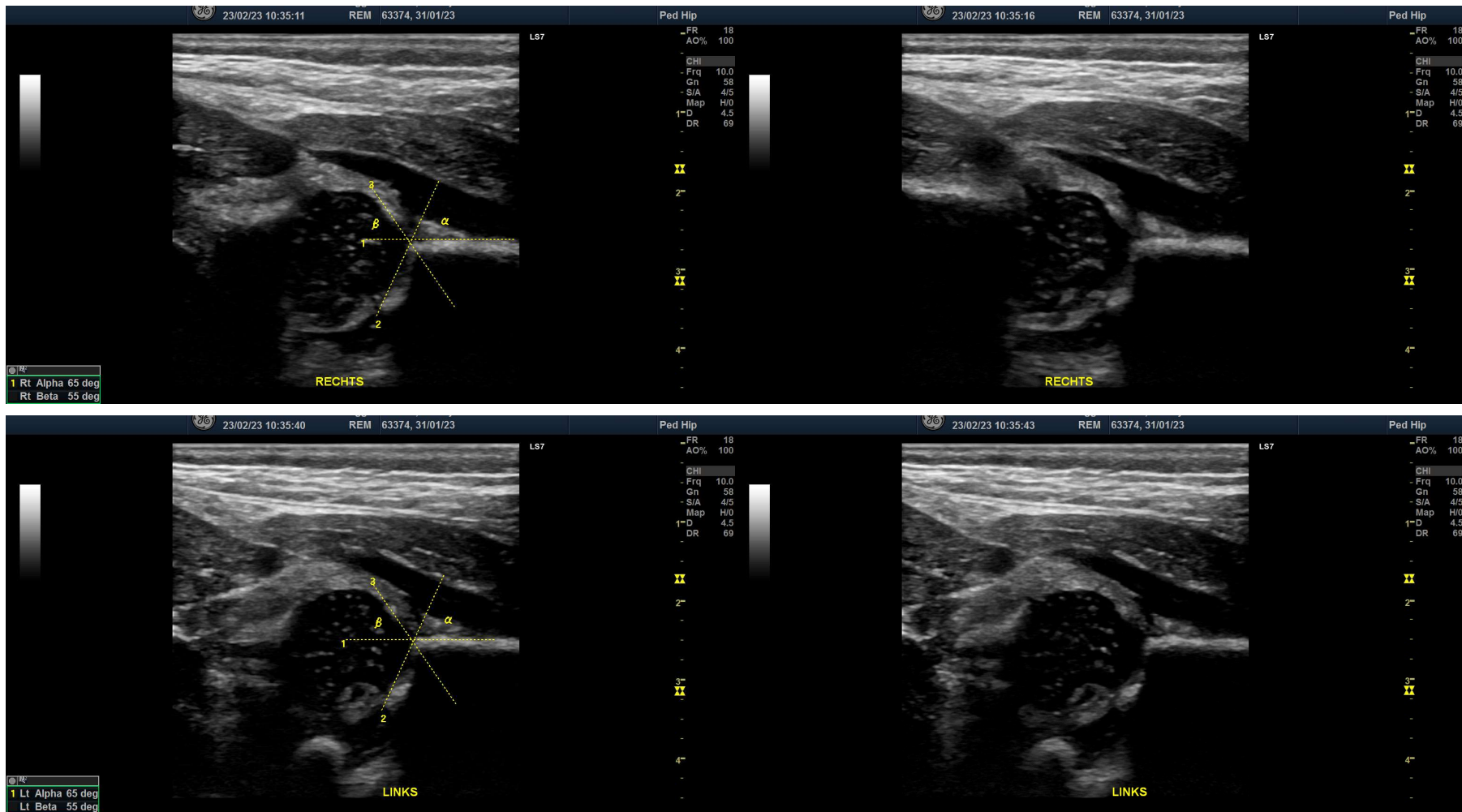
Quote from Skill Program 6:

“...After the 5-year period has expired, the certificate of competency for all specialist groups, including holders of the specialty “Pediatric Radiology”, will be renewed for a further five years if within this period a theoretical further training course of at least 8 credits as defined by the “Commission Hip Sonography according to Graf” has been completed and sufficient quality practical work can be demonstrated.”

Submit 20 cases via email in PDF format/Zip file by
2 months before the start of the course, 10 of which are type I and
10 non-type I hips

Quote from Skill Program 5. 2:

"...For this purpose, 20 examinations with findings reports and images carried out independently within the last 2 years (half of which are not hip type 1 according to Graf) must be submitted to the "Commission Hip Sonography according to Graf" for assessment[1]."



4 “best” images on one page per case in DIN A4 landscape format, e.g. in Word with a magnification factor of 32% (can vary depending on the device) and in right orientation or right = cranial, one measured and one unmeasured.

HüftsonoGRAFie modifiziert nach SMOPP®

Name 2227657


Geb. Datum 29.06.2022 Alter 7 Wochen Testdatum 16.08.2022

Anamnese/Klinik SRO

SVUPP
ASEPA
ASEPP

*SMOPP Swiss Mangolan Pediatric Project www.smopp.net

SMOPP	Graf	Alter	Knöcherna Form-gebung	Knöcherna Erkernorm	Knorpeliger Erkernorm	#	#	Procedere	
Gruppe	Typ								
A	Ia	Reife Hüfte	jedes	gut	eckig x	übergreifend	> 60°	< 55°	stabil
	Ib				stumpf ()	x+()	> 55°	> 55°	
B	IIa	Physiologisch unreif	bis 12. Woche (ab 6.-12. Woche)	ausreichend	rund	breit übergreifend	50°-59°	> 55°	Kontrolle
	IIb								
C	IIIa	Reifungsdefekt		mangelhaft		verringert übergreifend			Trennung
	IIIb	Verknöcherungsverzögerung	ab 4. Monat						
	IIIc	Gefährdet	jedes	hochgradig mangelhaft	rund bis flach	noch übergreifend	43°-49°	> 77°	
	IIIe	Am degenerieren		schlecht		verringert		> 77°	
D	IVa	Dezentriert			flach	nach ↑ verdrängt ohne Strukturstörung	< 43°		Reparatur
	IVb					nach ↑ verdrängt mit Strukturstörung			
	IV					nach ↓ verdrängt mit Strukturstörung			



links: X rechts: 0

stabil instabil

Beurteilung / Procedere

Hüfte Typ I nach Graf bds.

Ärztin/Arzt

Dr. med. Veit Vassen

- Written report of findings per case, e.g. using the SVUPP diagnostic sheet or your own findings template
- Classification exclusively according to Graf, no ABCD scheme!
- For physiologically immature hips or pathological hips: specify the procedure.